

Calcium Hydroxylapatite Combined with Microneedling and Ascorbic Acid is Effective for Treating Stretch Marks

Gabriela Casabona, MD
Paula Marchese, MD

Background: Stretch marks can have a negative psychological impact on some individuals. Methods are available for treating stretch marks, but high-quality evidence supporting their use is limited. We treat stretch marks using injections of diluted calcium hydroxylapatite (CaHA, Radiesse) filler combined with microneedling and topical ascorbic acid. This retrospective study evaluated the effectiveness of this combined therapy.

Methods: Subjects presented with red ($n = 25$) or white ($n = 10$) striae on their buttocks, thighs, knees, abdomen, and breasts. CaHA filler was diluted 1:1 with lidocaine 2% without epinephrine. A maximum of 3.0 mL of filler was injected per patient at all skin depths using a 23G needle. This was immediately followed by microneedling and topical application of 20% ascorbic acid. Microneedling with ascorbic acid was repeated after 1 and 2 months. Skin biopsies were obtained from a patient who later underwent abdominoplasty.

Results: The mean (\pm SD) pretreatment Manchester Scar Scale scores were 12.0 (± 0.8), decreasing to 7.1 (± 1.4) 1 month after the final treatment, indicating improvement in stretch mark appearance ($P < 0.001$). Subjects were very satisfied ($n = 22$; 62.9%), satisfied ($n = 8$; 22.9%), neither satisfied nor dissatisfied ($n = 4$; 11.4%), or unsatisfied ($n = 1$; 2.8%) with their treatment results. Analysis revealed a significant correlation between Scar Scale scores and Patient Satisfaction scores ($r = 0.483$; $P = 0.003$). Skin biopsies showed increased quantity and quality of collagen and elastin fibers in areas treated with combination therapy. Procedures were well tolerated.

Conclusion: Combining 1:1 diluted CaHA with microneedling and topical ascorbic acid is safe and effective for treating stretch marks. (*Plast Reconstr Surg Glob Open* 2017;5:e1474; doi: 10.1097/GOX.0000000000001474; Published online 26 September 2017.)

INTRODUCTION

Striae distensae (stretch marks) are a permanent type of dermal scarring. The unattractive appearance of stretch marks may have a significant negative psychological impact on some individuals. Although their exact etiology is unknown, the incidence of stretch marks is often associ-

ated with rapid growth, abrupt changes in weight, and the use of corticosteroids.¹ Consequently, they occur primarily among adolescents, obese individuals, and pregnant women. By the third trimester, approximately 90% of pregnant women develop stretch marks on their abdomen and/or breasts.²

Striae generally follow cleavage lines that are transverse to the direction of the greatest tension, where the tissue is the weakest and least able to withstand mechanical stress.³ They are initially red (striae rubrae), later becoming white and more atrophic (striae albae).^{1,4} Histologically, inflammatory changes are initially evident with dermal edema and perivascular lymphocytic cuffing followed by epidermal atrophy and loss of rete ridges.⁴ Stretch marks are distinguished from normal skin by densely packed

From the Clínica Vida, São Paulo, SP, Brazil.

Received for publication April 17, 2017; accepted July 10, 2017.

Presented at the International Master Course on Aging Science World Congress, 26–29 January 2017, Paris, France; 15th Annual Aesthetic & Anti-Aging Medicine World Congress, 6–8 April 2017, Monte Carlo, Monaco.

Copyright © 2017 The Authors. Published by Wolters Kluwer Health, Inc. on behalf of The American Society of Plastic Surgeons. This is an open-access article distributed under the terms of the Creative Commons Attribution-Non Commercial-No Derivatives License 4.0 (CCBY-NC-ND), where it is permissible to download and share the work provided it is properly cited. The work cannot be changed in any way or used commercially without permission from the journal.

DOI: 10.1097/GOX.0000000000001474

Disclosure: Dr. Casabona is a member of the speaker's bureau for Merz Pharmaceuticals and Allergan, Inc., but has no conflicts of interest to disclose related to the present study. The Article Processing Charge was paid for by Merz Pharmaceuticals GmbH, Frankfurt am Main, Germany.

areas of thin, horizontally arranged bundles of collagen lying parallel to the skin surface.⁴ Compared with normal skin, the number of vertical fibrillin fibers adjacent to the dermal-epidermal junction and elastin fibers in the papillary dermis are significantly reduced within stretch marks.⁴

A number of different methods are available for treating stretch marks (Table 1); however, high-quality evidence for effective and long-lasting therapies is limited or lacking.^{5,6} Thus, there are no consensus guidelines for treating striae. The lack of effective treatment results are either due to the permanence of skin atrophy or poor improvement in skin color.

Microneedling is one method of treating stretch marks that works by stimulating intradermal collagen production.⁷ Microneedling is also a means for achieving trans-epidermal drug delivery.^{8,9} Ascorbic acid, which also enhances the production of normal collagen, can be delivered in this manner.¹⁰ In recent years, hyaluronic acid fillers and poly-L-lactic acid fillers have been used to improve skin depression associated with atrophic acne scars¹¹⁻¹⁴ and can also be used to improve the appearance of atrophic stretch marks. Calcium hydroxylapatite (CaHA, Radiesse; Merz North America, Raleigh, N.C.) is another type of dermal filler composed of white 25–45 μM microspheres of CaHA suspended in a gel carrier.¹⁵ CaHA is considered both a dermal filler and a biostimulator due to its ability to induce neocollagenesis, ne elastogenesis, and angiogenesis.¹⁶⁻¹⁹ Currently, there are no reports describing the use of CaHA filler for treating atrophic striae.

To address both the skin atrophy and dyspigmentation associated with stretch marks, we have treated patients presenting to our clinic with striae using a combination of intra- and subdermal injections of 1:1 diluted CaHA, microneedling, and topical ascorbic acid. The objective of this retrospective chart review was to evaluate the effectiveness of this combined therapy for improving the appearance of stretch marks.

METHODS

Treatments

All treatments were performed at the Clínica Vida, São Paulo, Brazil, from January 2010 to July 2015. The study subjects (N = 35) were 21 to 34 years old with red (n = 25; 71.4%) or white (n = 10; 28.6%) stretch marks on their buttocks, thighs, knees, abdomen, and breasts. Patients were treated during 3 sessions over an 8-week period (Fig. 1). During the first session, an anesthetic cream containing 7% tetracaine and 7% lidocaine (Pliaglis Cream, Galderma Laboratories, Fort Worth, Tex.; maximum of 10g/session) was applied to the planned treatment area 30 minutes before treatment. The area was also cleansed with an alcoholic chlorhexidine 0.5% solution.

The first session included the dermal injection of 1.5mL CaHA diluted 1:1 with 1.5mL of lidocaine 2% without epinephrine (Cristalia Produtos Quimicos Farmaceuticos Ltda., Santa Cruz, Brazil). Using a microbolus technique, a maximum of 3.0mL of the diluted filler was injected per patient at all depths from subcutaneous to

Table 1. Available Methods for Treating Stretch Marks

Treatment	Mechanism of Action
Creams and lotions containing various plant extracts, vitamins, and proteins ⁵⁰	Available scientific data are insufficient to demonstrate these products are effective.
Tretinoin 0.1% cream ⁵¹	Increases collagen
Glycolic acid peels ⁵¹	Increases collagen
Topical ascorbic acid ¹⁰	Increases collagen and elastin fibers
Intense pulsed light ⁵²	Increases collagen
Lasers ⁵³	Increases collagen and elastin fibers
Microdermabrasion ⁵⁴	Increases collagen and elastic fibers
Microneedling ⁵⁵	Increases collagen
Injection of autologous pluripotent cells ⁵⁶	Atrophic scar tissue is gradually replaced by normal appearing skin.

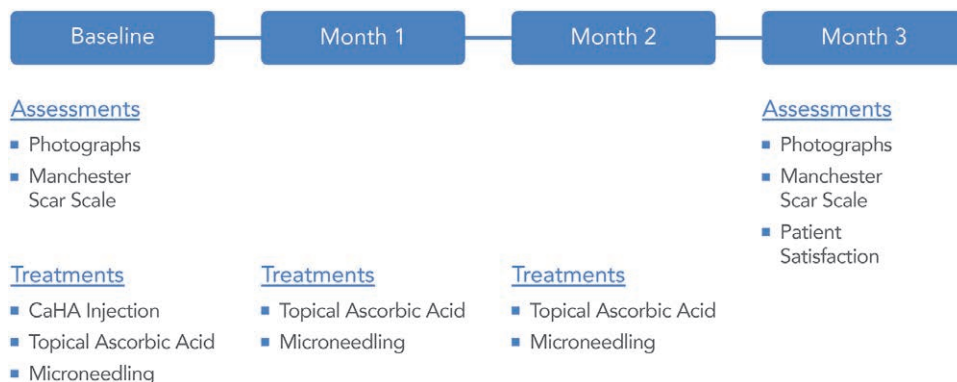


Fig. 1. Treatments and assessments. This diagram shows the treatments and assessments performed for each subject.

superficial dermis using a 1 ¼-inch, 23 gauge needle. An aspiration test was performed before each injection. The CaHA injections were followed by vigorous massaging of the area.

CaHA injections were immediately followed by microneedling using needle length of 2.0 mm and a vibration setting of 7 (~85–90 time/sec),²⁰ which produced more microneedling and less dermabrasion (Dermapen Fractional Micro Needle System; DermapenWorld™, Fort Lauderdale, Fla.). Microneedling was performed in conjunction with the topical application of 20% ascorbic acid (Energy C Professional Treatment, Me-soestetic USA; North Hollywood, Calif.). Ascorbic acid was applied using a sterilized disposable brush before each microneedling pass (N = 20) with an endpoint of mild bleeding (Fig. 2). At the end of the treatment session, the area was cleansed and a plastic bandage was left on for 4 hours. Afterward, patients were advised to

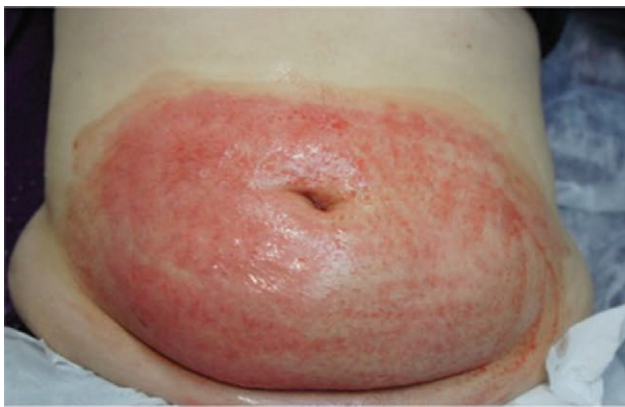

Fig. 2. Microneedling. Microneedling was performed in conjunction with 20% ascorbic acid applied using a sterilized disposable brush before each microneedling pass. The endpoint was mild bleeding (after approximately 20 passes).

Table 2. Manchester Scar Scale

Parameter	Score
Color	
Perfect	1
Slight mismatch	2
Obvious mismatch	3
Gross mismatch	4
Finish	
Matte	1
Shiny	2
Contour	
Flush with surrounding skin	1
Slightly raised or indented	2
Hypertrophic	3
Keloid	4
Distortion	
None	1
Mild	2
Moderate	3
Severe	4
Texture	
Normal	1
Just palpable	2
Firm	3
Hard	4

The original scale also includes a visual analogue scale of 1–10 that describes the overall cosmetic scar appearance.²¹

Table 3. Manchester Scar Scale Scores, N = 35

	Mean (SD)	Median (min–max)	Significance*
Manchester Scar Scale, N = 35			
Pretreatment scores	12.0 (0.8)	12.0 (11.0, 13.0)	—
Posttreatment scores	7.1 (1.4)	6.0 (6.0, 10.0)	—
Change	-4.9 (1.4)	-5.0 (-7.0, -2.0)	<i>P</i> < 0.001

*Wilcoxon test for related samples.

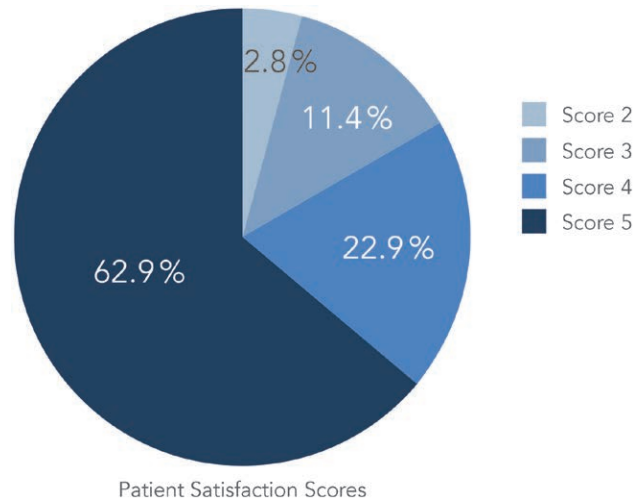


Fig. 3. Patient Satisfaction Scores. Most subjects (85.8%) were satisfied or very satisfied with the appearance of their stretch marks following treatment. Satisfaction scoring: 1 = very unsatisfied; 2 = unsatisfied; 3 = OK (neither satisfied nor unsatisfied); 4 = satisfied; 5 = very satisfied.

avoid sun exposure for at least 6 months. During the 2 subsequent treatment sessions at months 1 and 2, subjects underwent microneedling with ascorbic acid application only.

Assessments

Changes in stretch mark appearance were assessed using the Manchester Scar Scale at baseline and 1 month after the last treatment session (Table 2). Patient satisfaction with the aesthetic results was assessed using a 5-point scale ranging from 1 (very unsatisfied) to 5 (very satisfied). Safety assessments included careful examination of the treated areas and reports of adverse events.

One subject with abdominal stretch marks later decided to undergo abdominoplasty to remove excess lax skin following pregnancy. After receiving informed consent, biopsies for histological analysis were obtained from the skin scheduled to be removed. For comparison purposes, the subject received treatment with microneedling and ascorbic acid in an area on one side of the umbilicus and CaHA combined with microneedling and ascorbic acid on the contralateral side. Biospecimens from an untreated area were also collected. Tissue samples were stained with hematoxylin and eosin, Masson’s trichrome and Verhoeff’s stains and assessed by a dermatopathologist for differences in collagen and elastin

Table 4. Patient Satisfaction by Treatment Area*

Treatment area	Very Satisfied	Satisfied	Neither Satisfied nor Unsatisfied	Unsatisfied	Very Unsatisfied
Buttocks (%)	75	0	25	0	0
Thighs (%)	63	38	0	0	0
Knees (%)	25	25	50	0	0
Abdomen (%)	69	25	0	0	0
Breasts (%)	67	33	0	0	0

*Some subjects were treated in more than 1 area.

formation. Posttreatment assessments in the quality and quantity of collagen and elastin fibers included changes in fiber numbers, volume, and thickness.

Changes in Manchester Scar Scale scores were analyzed using Wilcoxon signed-rank test. Spearman’s rank correlation coefficient was used to determine the relationship between Manchester Scar Scale scores and Patient Satisfaction scores.

RESULTS

Efficacy

Manchester Scar Scale scores range from a possible high of 18 to a low of 5, with lower scores indicating better aesthetic appearance (the 10-point visual analog scale was not used).²¹ All 35 patients had significantly decreased Manchester Scar Scale scores at the end of the study (Table 3). The mean (\pm SD) pretreatment scores were 12.0 (\pm 0.8), decreasing to 7.1 (\pm 1.4) at 1 month following the final treatment ($P < 0.001$). Subjects were very satisfied ($n = 22$; 62.9%), satisfied ($n = 8$; 22.9%), neither satisfied nor dissatisfied ($n = 4$; 11.4%), or unsatisfied ($n = 1$; 2.8%; Fig. 3). The greatest satisfaction was from subjects treated for striae on the buttocks, abdomen, and breasts (Table 4). There was no apparent difference between striae types.

The improved aesthetic appearance of striae was related to patient satisfaction. Statistical analysis revealed a significant correlation between Manchester Scar Scale scores and Patient Satisfaction scores ($r = 0.483$; $P = 0.003$; Fig. 4).

Examination of stained skin biopsies revealed an increase in the quantity and quality of dermal collagen and elastin fibers in areas treated with the combination therapy versus untreated skin and areas treated with only microneedling and ascorbic acid (Fig. 5). The epidermis showed greater thickening in tissue receiving the combination treatment. There was an increase in the number of collagen and elastin fibers as well as an apparent increase in volume caused by increased fiber thickness. When the subepidermal (papillary dermis) areas were compared, the areas treated with microneedling and combined therapies also showed the presence of increased collagen. Improvements in the appearance of striae observed 1 month after the last treatment session are evident in the subjects in Figures 6 and 7.

For the purpose of statistical analysis, all subjects were evaluated 1 month after the final treatment with microneedling and ascorbic acid; however, some patients have maintained their initial results for up to 4 years. This would be expected as the biopsy results demonstrated neocollagenesis and elastogenesis. An 18-year-old subject who was treated on her thighs and buttocks and evaluated after 2 years is shown in Figure 8. At that time, her Manchester Scar Scale

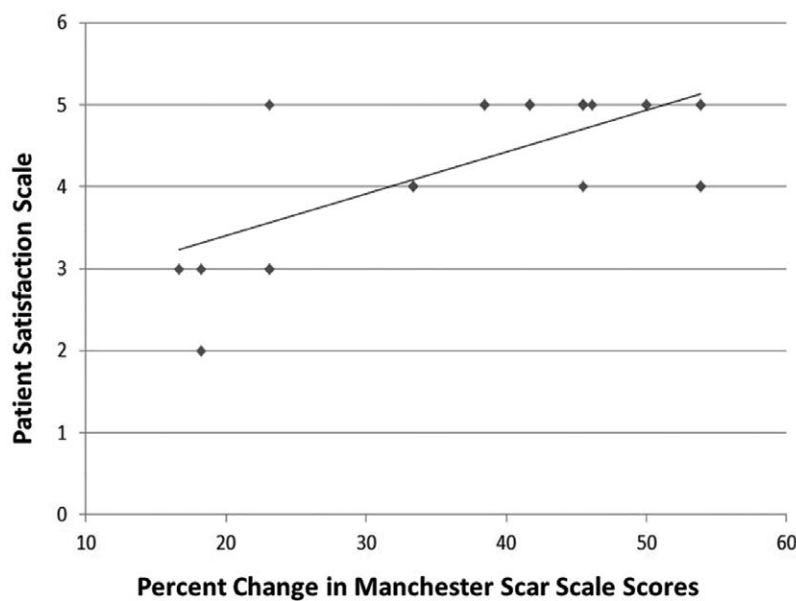


Fig. 4. Correlation of Manchester Scar Scale and Patient Satisfaction Scores. Percentage improvement in Manchester Scar Scale scores was significantly correlated with improvement in Patient Satisfaction Scale scores ($r = 0.483$; $P = 0.003$).

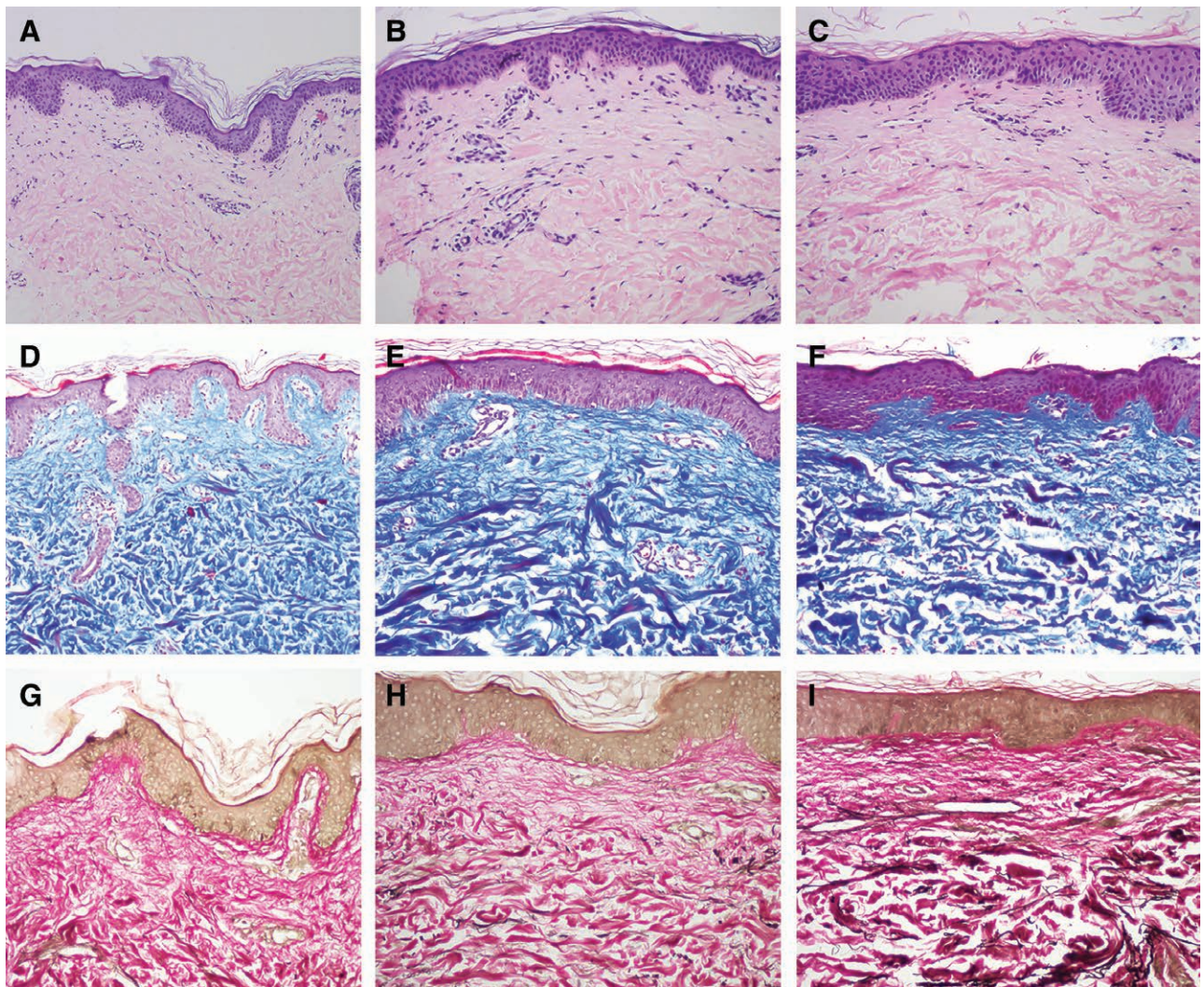


Fig. 5. Histology analysis. Biopsies of treated tissue revealed an increase in the quantity and quality of dermal collagen and elastin fibers in areas treated with the combination therapy vs. untreated skin and areas treated with only microneedling and ascorbic acid. A, D, and G: normal, untreated skin; B, E, and H: tissue treated with microneedling and ascorbic acid only; C, F, and I: tissue treated with 1:1 diluted CaHA injection, microneedling, and ascorbic acid.

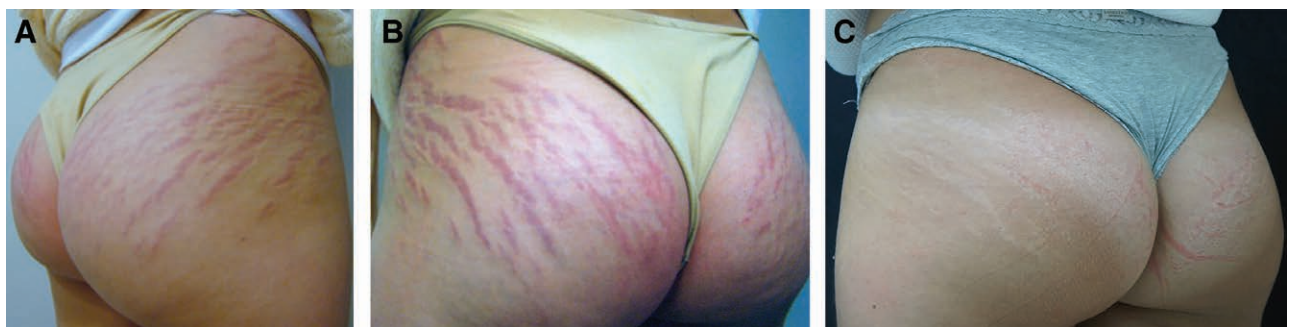

Fig. 6. Pre- and posttreatment images. Pre- and posttreatment images of a 20-year-old subject who developed acute deep striae rubrae in the gluteus region after course of oral prednisone. Baseline appearance of striae (A, B) is much improved after treatment (C) with 1:1 diluted CaHA followed by 3 sessions of topical ascorbic acid and microneedling.

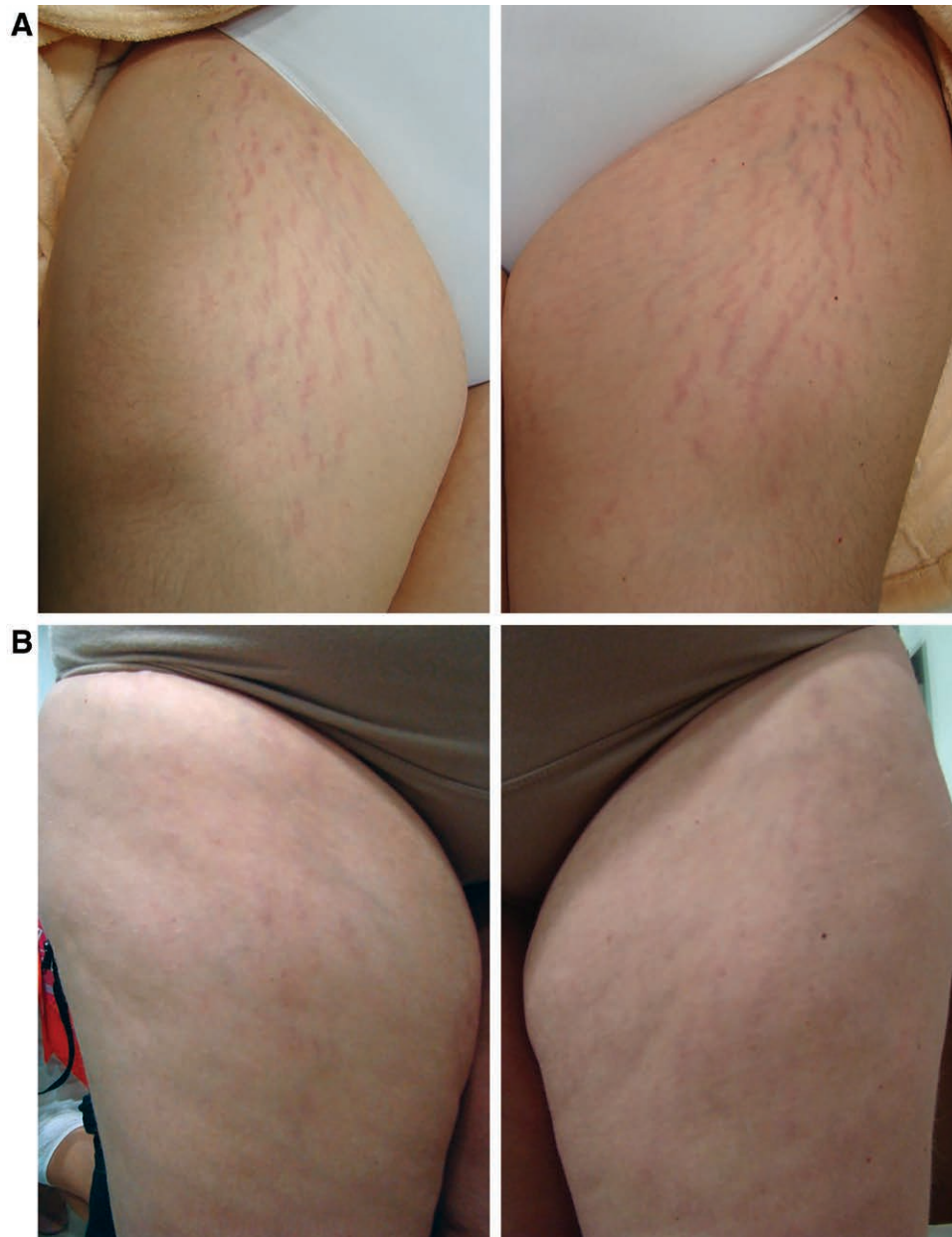


Fig. 7. Pre- and Post-treatment Images. Pre- and post-treatment images of a 32-year-old subject who developed acute deep striae rubrae in the anterior thigh after pregnancy. Baseline appearance of striae (A) is much improved after treatment with 1:1 diluted CaHA followed by 3 sessions of topical ascorbic acid and microneedling (B).

score was 9 and her satisfaction score was 4 (satisfied). A small number of patients have required retreatment with microneedling and ascorbic acid after 2 years because of recurring skin atrophy.

Safety

Two subjects with Fitzpatrick skin type III developed postinflammatory hyperpigmentation. Both were treated for 30 days with a whitening cream (Kligman's formula) with complete resolution. Bruising ($n = 32$) and erythema ($n = 35$) resolved within 7 days, and mild pain resolved within 2 days. There were no serious adverse events.

DISCUSSION

The objective of this retrospective study was to assess the effectiveness of combining intra- and subdermal injections of 1:1 diluted CaHA and microneedling with topical ascorbic acid for improving the appearance of red and white stretch marks. As applied in the current study, Manchester Scar Scale scores range from a possible high of 18 to a low of 5, with lower scores indicating better aesthetic appearance. One month after the final treatment, mean subject scores decreased from 12.0 (range, 11.0–13.0) to 7.1 (range, 6.0–10.0), indicating significant aesthetic improvement in striae appearance ($P < 0.001$). Not surpris-

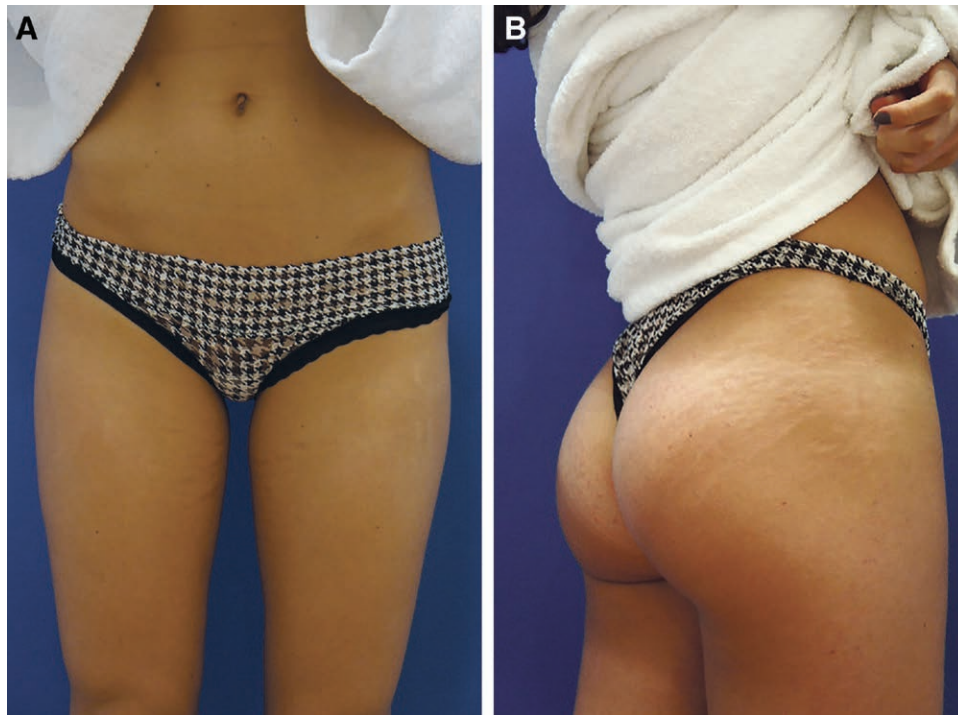


Fig. 8. Two-year posttreatment Images. An 18-year-old subject who was treated on the thighs and buttocks was evaluated after 2 years. At that time, her Manchester Scar Scale score was 9 and her satisfaction score was 4 (satisfied).

ingly, these clinical improvements were highly correlated with patients' satisfaction.

Skin biopsies revealed an increase in the quantity and quality of dermal collagen and elastin fibers in areas treated with the combination therapy versus untreated skin and areas treated with microneedling and ascorbic acid alone. Combined treatments were well tolerated. Reported adverse events from combined treatments seem to reflect those of the individual treatments.

Regardless of the type of therapy used, the goal for treating the atrophic appearance of striae is to stimulate collagen production. Microneedling and dermal filler injections stimulate collagen production via the same signal transduction cascade that occurs following any skin trauma.²²⁻²⁴ This wound-healing process occurs in several predictable phases.^{25,26}

Initially, injury disrupts the vascular endothelium resulting in platelet activation followed by the release of growth factors.²⁷ Subsequently, there is an influx of inflammatory polymorphonuclear leukocytes. These, together with fibroblasts and endothelial cells, aggregate on the fibrin framework formed by platelet activation.²⁷ Secretion of additional cytokines and growth factors promote fibroblast proliferation, angiogenesis, and migration of keratinocytes. During the proliferation stage, fibroblasts are also responsible for elastin production and organization of the extracellular matrix.²⁷ Fibroblasts multiply and increase the production of collagen type III. Eventually, collagen type III is converted into collagen type I, which gradually tightens.²⁸⁻³⁰ Treating the skin with microneedling promotes the removal of old damaged collagen and

increases new collagen synthesis beneath the epidermis, tightening the skin affected by stretch marks and improving atrophy.^{31,32}

Microneedling is also a proven means for delivering medications, such as ascorbic acid, into the skin.³³ Ascorbic acid (vitamin C) is essential for the production of normal collagen. It functions as an essential cofactor for the enzymes lysyl-hydroxylase and prolyl-hydroxylase, which are required for the posttranslational processing of collagen types I and III.³⁴ Ascorbic acid also stimulates collagen production in the dermis by increasing fibroblast proliferation.³⁵ It therefore seems likely that ascorbic acid can improve the atrophic appearance of stretch marks. At the level of gene expression, ascorbic acid has also been shown to upregulate collagen synthesis and increase the synthesis of the inhibitor of metalloproteinase I, which decreases ultraviolet-induced collagen degradation.³⁶

For more than a decade, CaHA has been used for facial rejuvenation and HIV-associated lipoatrophy by correcting moderate-to-severe wrinkles and folds and soft-tissue volume loss.³⁷⁻⁴³ When injected more superficially in its diluted or hyper-diluted form, it has also demonstrated effectiveness in treating volume loss and skin laxity in nonfacial areas, such as neck and décolletage, upper arms, buttocks, thighs, and abdomen.^{19,44,45}

In the skin, CaHA results in active, physiologic remodeling of the extracellular matrix by stimulating a 2-step process, whereby collagen type I gradually replaces collagen type III.¹⁸ Increased elastin synthesis stimulated by CaHA also indicates active remodeling. The injection of diluted CaHA (1:1 and 1:0.6 dilutions with 2% lidocaine solution)

into the buttocks and thighs has been shown to increase neocollagenesis, with the highest conversion of collagen type III into collagen type I occurring at 90 days with significant improvement in the appearance of cellulite.⁴⁶ Although several published reports have described the beneficial effects of CaHA for treating atrophic acne scars,^{47–49} a review of the literature failed to identify any reports describing the use of CaHA for treating stretch marks.

CaHA is designed to be injected into deeper planes of the skin, such as the subdermal layer.¹⁵ We have observed that injecting diluted CaHA (1:0.5 to 1:0.25) more superficially can produce a yellowish discoloration of the skin. We therefore hypothesized that, in addition to increasing volume to atrophic striae, the use of CaHA may also add color to provide a more natural appearance of white striae.

This study includes several novel findings. It is the first to demonstrate the effectiveness of 1:1 diluted CaHA combined with topical ascorbic acid and microneedling for improving the aesthetic appearance of both white and red stretch marks. This combination provides 3 potential mechanisms for improving the atrophic appearance of stretch mark tissue: (1) mechanical stimulation of neocollagenesis and neolastogenesis by CaHA microspheres^{18,19}; (2) recruitment of immune cells and subsequent release of growth factors following damage of the skin barrier through microneedling²⁷; (3) delivery of ascorbic acid to enhance collagen synthesis.³⁵ Our encouraging results suggest that this combined treatment technique may produce better results than those obtained when each technique is performed alone. Future studies should include control groups to better demonstrate the beneficial effects of combined treatments and assess long-term results.

CONCLUSIONS

Diluted CaHA, microneedling, and topical ascorbic acid can each increase collagen production in the skin. The results of this retrospective study show that combining these procedures is a safe and effective treatment for both red and white striae.

Gabriela Casabona, MD

Clínica Vida

Rua Dr. Veiga Filho, 350

São Paulo, Brazil

E-mail: grcasabona@uol.com.br

ACKNOWLEDGMENT

The author acknowledges the editorial assistance of Dr. Carl Hornfeldt during the preparation of this article with funding provided by Merz Pharmaceuticals GmbH, Frankfurt am Main, Germany.

REFERENCES

1. Elsaie ML, Baumann LS, Elsaie LT. Striae distensae (stretch marks) and different modalities of therapy: an update. *Dermatol Surg.* 2009;35:563–573.
2. Barankin B, Silver SG, Carruthers A. The skin in pregnancy. *J Cutan Med Surg.* 2002;6:236–240.
3. Lee KS, Rho YJ, Jang SI, et al. Decreased expression of collagen and fibronectin genes in striae distensae tissue. *Clin Exp Dermatol.* 1994;19:285–288.
4. Singh G, Kumar LP. Striae distensae. *Indian J Dermatol Venereol Leprol.* 2005;71:370–372.
5. Liu L, Ma H, Li Y. Interventions for the treatment of stretch marks: a systematic review. *Cutis.* 2014;94:66–72.
6. Al-Himdani S, Ud-Din S, Gilmore S, et al. Striae distensae: a comprehensive review and evidence-based evaluation of prophylaxis and treatment. *Br J Dermatol.* 2014;170:527–547.
7. Park KY, Kim HK, Kim SE, et al. Treatment of striae distensae using needling therapy: a pilot study. *Dermatol Surg.* 2012;38:1823–1828.
8. Prausnitz MR. Microneedles for transdermal drug delivery. *Adv Drug Deliv Rev.* 2004;56:581–587.
9. Henry S, McAllister DV, Allen MG, et al. Microfabricated microneedles: a novel approach to transdermal drug delivery. *J Pharm Sci.* 1998;87:922–925.
10. Hinek A, Kim HJ, Wang Y, et al. Sodium L-ascorbate enhances elastic fibers deposition by fibroblasts from normal and pathologic human skin. *J Dermatol Sci.* 2014;75:173–182.
11. Zaleski-Larsen LA, Fabi SG, McGraw T, et al. Acne scar treatment: a multimodality approach tailored to scar type. *Dermatol Surg.* 2016;42:S139–S149.
12. Goodman GJ, Van Den Broek A. The modified tower vertical filler technique for the treatment of post-acne scarring. *Australas J Dermatol.* 2016;57:19–23.
13. Beer K. A single-center, open-label study on the use of injectable poly-L-lactic acid for the treatment of moderate to severe scarring from acne or varicella. *Dermatol Surg.* 2007;33:S159–167.
14. Karnik J, Baumann L, Bruce S, et al. A double-blind, randomized, multicenter, controlled trial of suspended polymethylmethacrylate microspheres for the correction of atrophic facial acne scars. *J Am Acad Dermatol.* 2014;71:77–83.
15. *Radiesse Injectable Implant. [Instructions for Use, 2016].* Raleigh, N.C.: Merz North America, Inc.
16. Marmur ES, Phelps R, Goldberg DJ. Clinical, histologic and electron microscopic findings after injection of a calcium hydroxylapatite filler. *J Cosmet Laser Ther.* 2004;6:223–226.
17. Berlin AL, Hussain M, Goldberg DJ. Calcium hydroxylapatite filler for facial rejuvenation: a histologic and immunohistochemical analysis. *Dermatol Surg.* 2008;34:S64–S67.
18. Yutskovskaya Y, Kogan E, Leshunov E. A randomized, split-face, histomorphologic study comparing a volumetric calcium hydroxylapatite and a hyaluronic acid-based dermal filler. *J Drugs Dermatol.* 2014;13:1047–1052.
19. Yutskovskaya YA, Kogan EA. Improved neocollagenesis and skin mechanical properties after injection of diluted calcium hydroxylapatite in the neck and décolletage: a pilot study. *J Drugs Dermatol.* 2017;16:68–74.
20. *Dermapen Fractional Micro Needle System.* Fort Lauderdale, FL: DermapenWorld™.
21. Beausang E, Floyd H, Dunn KW, et al. A new quantitative scale for clinical scar assessment. *Plast Reconstr Surg.* 1998;102:1954–1961.
22. Falabella AF, Falanga V. Wound healing. In: Feinkel RK, Woodley DT, eds. *The Biology of the Skin.* New York, N.Y.: Parthenon; 2000:281–299.
23. Tejero-Trujique R. Understanding the final stages of wound contraction. *J Wound Care.* 2001;10:259–264.
24. Johnstone CC, Farley A. The physiological basics of wound healing. *Nurs Stand.* 2005;19:59–65; quiz 66.
25. Lynch SE, Colvin RB, Antoniades HN. Growth factors in wound healing. Single and synergistic effects on partial thickness porcine skin wounds. *J Clin Invest.* 1989;84:640–646.
26. Tran KT, Griffith L, Wells A. Extracellular matrix signaling through growth factor receptors during wound healing. *Wound Repair Regen.* 2004;12:262–268.

27. Janis JE, Harrison B. Wound healing: part I. Basic science. *Plast Reconstr Surg*. 2016;138:9–17S.
28. Ruszczak Z. Effect of collagen matrices on dermal wound healing. *Adv Drug Deliv Rev*. 2003;55:1595–1611.
29. Faler BJ, Macsata RA, Plummer D, et al. Transforming growth factor-beta and wound healing. *Perspect Vasc Surg Endovasc Ther*. 2006;18:55–62.
30. Martin P, Leibovich SJ. Inflammatory cells during wound repair: the good, the bad and the ugly. *Trends Cell Biol*. 2005;15:599–607.
31. Fernandes D. Percutaneous collagen induction: an alternative to laser resurfacing. *Aesthet Surg J*. 2002;22:307–309.
32. Aust MC, Fernandes D, Kolokythas P, et al. Percutaneous collagen induction therapy: an alternative treatment for scars, wrinkles, and skin laxity. *Plast Reconstr Surg*. 2008;121:1421–1429.
33. McCrudden MT, McAlister E, Courtenay AJ, et al. Microneedle applications in improving skin appearance. *Exp Dermatol*. 2015;24:561–566.
34. Nusgens BV, Humbert P, Rougier A, et al. Topically applied vitamin C enhances the mRNA level of collagens I and III, their processing enzymes and tissue inhibitor of matrix metalloproteinase 1 in the human dermis. *J Invest Dermatol*. 2001;116:853–859.
35. Phillips CL, Combs SB, Pinnell SR. Effects of ascorbic acid on proliferation and collagen synthesis in relation to the donor age of human dermal fibroblasts. *J Invest Dermatol*. 1994;103:228–232.
36. Stamford NP. Stability, transdermal penetration, and cutaneous effects of ascorbic acid and its derivatives. *J Cosmet Dermatol*. 2012;11:310–317.
37. Muti GF, Astolfi G, Renzi M, et al. Calcium hydroxylapatite for augmentation of face and hands: a retrospective analysis in Italian subjects. *J Drugs Dermatol*. 2015;14:948–954.
38. Loghem JV, Yutskovskaya YA, Philip Werschler W. Calcium hydroxylapatite: over a decade of clinical experience. *J Clin Aesthet Dermatol*. 2015;8:38–49.
39. Emer J, Sundaram H. Aesthetic applications of calcium hydroxylapatite volumizing filler: an evidence-based review and discussion of current concepts: (part 1 of 2). *J Drugs Dermatol*. 2013;12:1345–1354.
40. Smith S, Busso M, McClaren M, et al. A randomized, bilateral, prospective comparison of calcium hydroxylapatite microspheres versus human-based collagen for the correction of nasolabial folds. *Dermatol Surg*. 2007;33:S112–21; discussion S121.
41. Bass LS, Smith S, Busso M, et al. Calcium hydroxylapatite (Radiesse) for treatment of nasolabial folds: long-term safety and efficacy results. *Aesthet Surg J*. 2010;30:235–238.
42. Marmur ES, Taylor SC, Grimes PE, et al. Six-month safety results of calcium hydroxylapatite for treatment of nasolabial folds in Fitzpatrick skin types IV to VI. *Dermatol Surg*. 2009;35:1641–1645.
43. Silvers SL, Eviatar JA, Echavez MI, et al. Prospective, open-label, 18-month trial of calcium hydroxylapatite (Radiesse) for facial soft-tissue augmentation in patients with human immunodeficiency virus-associated lipoatrophy: one-year durability. *Plast Reconstr Surg*. 2006;118:34S–45S.
44. Cogorno Wasylkowski V. Body vectoring technique with Radiesse for tightening of the abdomen, thighs, and brachial zone. *Clin Cosmet Investig Dermatol*. 2015;8:267–273.
45. Amselem M. Radiesse: a novel rejuvenation treatment for the upper arms. *Clin Cosmet Investig Dermatol*. 2016;9:9–14.
46. Casabona G, Pereira G. Microfocused ultrasound with visualization and calcium hydroxylapatite for improving skin laxity and cellulite appearance. *Plast Reconstr Surg Glob Open* 2017;5:e1388.
47. Goldberg DJ, Amin S, Hussain M. Acne scar correction using calcium hydroxylapatite in a carrier-based gel. *J Cosmet Laser Ther*. 2006;8:134–136.
48. Jacovella PF. Use of calcium hydroxylapatite (Radiesse) for facial augmentation. *Clin Interv Aging*. 2008;3:161–174.
49. Tzikas TL. Evaluation of the Radiance FN soft tissue filler for facial soft tissue augmentation. *Arch Facial Plast Surg*. 2004;6:234–239.
50. Ud-Din S, McGeorge D, Bayat A. Topical management of striae distensae (stretch marks): prevention and therapy of striae rubrae and albae. *J Eur Acad Dermatol Venereol*. 2016;30:211–222.
51. Karia UK, Padhiar BB, Shah BJ. Evaluation of various therapeutic measures in Striae Rubra. *J Cutan Aesthet Surg*. 2016;9:101–105.
52. Bedewi AE, Khalafawy GE. The use of synchrotron infrared microspectroscopy to demonstrate the effect of intense pulsed light on dermal fibroblasts. *J Cosmet Laser Ther*. 2013;15:305–309.
53. Elsaie ML, Hussein MS, Tawfik AA, et al. Comparison of the effectiveness of two fluences using long-pulsed Nd:YAG laser in the treatment of striae distensae. Histological and morphometric evaluation. *Lasers Med Sci*. 2016;31:1845–1853.
54. Tehrani R. Microdermabrasion for striae distensae. *Indian J Dermatol Venereol Leprol*. 2006;72:59; author reply 59–59; author reply 60.
55. Singh A, Yadav S. Microneedling: advances and widening horizons. *Indian Dermatol Online J*. 2016;7:244–254.
56. Maiborodin I, Shevela A, Babko A, et al. Morphological substantiation of application of cellular technologies for correction of striae. *Health*. 2010;2:1430–1436.