

Minimally Invasive Percutaneous Collagen Induction

Desmond Fernandes, MB, BCh, FRCS(Edin)

The Shirnel Clinic and Department of Plastic Reconstructive Surgery, University of Cape Town, 822 Fountain Medical Centre, Heerengracht, Cape Town 8001, South Africa

We live in a time when more people are living to a greater age than ever before. At the same time, there is an accent on youth such that our patients are asking us to make them look as young as possible. Obviously, surgery helps restructure the face into a more youthful shape, but the old skin remains. Today, many patients come before they need surgery, searching for a rapid solution that will make them look 10 years younger. How do we help our older cosmetic patients or the much younger men and women who want to prolong their tenure in a youthful bracket?

This quest for younger-looking skin has spawned many different topical techniques that share the same principle of damaging the skin to cause fibrosis. The fibrosis then causes tightening of the skin. Historically, skin peels were the first method of skin rejuvenation. The principle of peeling is to destroy the epidermis partially or almost completely to damage the fibroblasts and dermal structures. This damage then sets up an inflammatory response proportional to the damage, which results in the deposition of collagen. Peeling sacrifices the epidermis to achieve the desired result. The experience with partial-depth burns misled many into believing that the epidermis is a self-renewing organ that rapidly grows over the damaged area, which is why peels

became progressively more destructive for the epidermis (eg, the deep phenol peel) until the accumulated problems forced clinicians to recognize that smoother skin comes at a very heavy price for many patients and also leads to a significant thinning of the skin many years later. The proponents of peeling looked only at the increase of collagen in the papillary and reticular dermis but did not pay any attention to the epidermis. The epidermis suffered by becoming less undulating due to the destruction of the dermal papillae and subsequent impaired nourishment and, in turn resulted in a thinner epidermis with fewer cells in the stratum spinosum than before treatment. The stratum corneum is then less likely to act as an efficient barrier, so it is not surprising that many patients feel that their skin is too dry for years after the treatment. Consequently, hydration of the dermis also is affected.

Lighter peels (eg, Jessner's and trichloroacetic acid (TCA)) were introduced, but the tightening of skin was less effective. For some reason, which is difficult to understand, clinicians in the late 1980s turned to laser to destroy the epidermis even more thoroughly to tighten the skin. We were told that laser would not present the same problems as the heavy phenol peels and that skin color and texture would be superior. Smoothing skin is still most effectively done by CO₂ laser through the aggressive heat damage that is caused. No other technique can match it, but at the same time, CO₂ laser causes the most complications. A significant problem is that deep treatments like this stimulate fibrosis rather than new, naturally oriented collagen formation. This fibrosis may result in a much whiter reflectance from the dermis, giving the skin an unnatural pallor. The sad fact is that several years after the treatment, the collagen will be

The author, a plastic and reconstructive surgeon practicing in Cape Town, is the medical consultant for Environ Cosmeceutics International and Vivida Closed Corporation (c.c.), Cape Town, South Africa. Vivida c.c. is the manufacturer of the Environ Roll-Cit. Dr. Fernandes has a financial interest in both of these companies.

E-mail address: des@environ.co.za

resorbed—as all scar collagen is—and fine wrinkles will start to show as a result of the thin epidermis with no dermal papillae. The impaired hydration of the skin means that it is not as plump as it could be and can look atrophic due to this excessive destruction.

Why destroy the epidermis to make the skin smoother? The epidermis is an extremely complex, highly specialized organ. It may be only 0.2 mm thick but it is our sole protection from the environment. We should never damage the epidermis unless the risk of leaving the epidermis intact is greater than the risk of removing it. Wrinkles are hardly a good excuse to destroy this wonderfully complex interface that we have with the world. Whatever we do, we should try to ensure that the basic normal architecture of the skin is never altered. To rejuvenate facial skin and really look young, we need a perfect epidermis with natural dermal papillae, good hydration, normal color, and normal resilience.

The problem with most treatments that are used is that only the face can successfully be treated. In addition, if the result after one treatment is inadequate, then a repeated treatment cannot easily be done. Clinicians have concentrated on rejuvenating the face, with the result that we get patients with a younger-looking face but with older hands, arms, and trunk. We need to treat not only the face but the hands, arms, trunk, and legs. Laser, however, has extremely limited indications for areas other than the face. Laser treatment is not real rejuvenation and will not satisfy patients who are looking for a more complete rejuvenation.

This article is devoted to a technique that lends itself to treatment of the face and the body to achieve collagen induction. Although this technique may seem new, we have had centuries of experience with

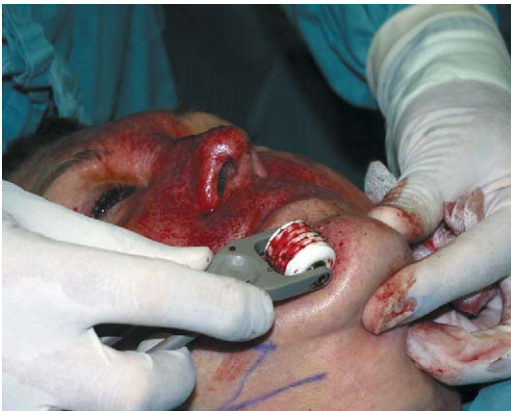

Fig. 1. Needling the face for refining wrinkles using the special tool designed for PCI.

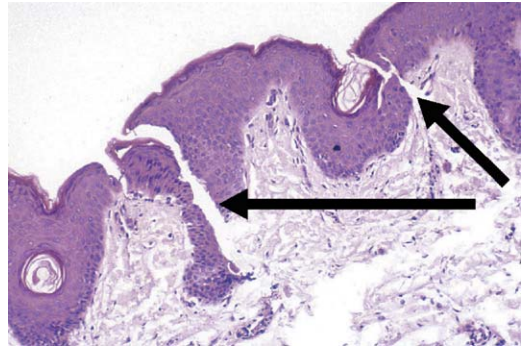


Fig. 2. Histologic section of skin showing puncture sites where the needle has penetrated (*arrows*) and generally divided cells from each other rather than cutting through the cells. The tracts are curved, reflecting the path of the needle as it rolls into and then out of the skin. The holes are about four cells wide and will heal rapidly. Note that the epidermis and particularly the stratum corneum is intact except for these tiny holes (hematoxylin-eosin, original magnification $\times 40$).

the technique of tattooing, but in this case, there is no pigment used. There are now a growing number of clinicians who believe that we can get closer to our patients' dreams of rejuvenation by pricking skin with needles to get percutaneous collagen induction (PCI).

Principles of the needling technique

Orentreich and Orentreich [1] described "subcision" as a way of building up connective tissue beneath retracted scars and wrinkles. The author [2], simultaneously and independently, used a similar technique to treat the upper lip by sticking a 15-gauge needle into the skin and then tunneling under the wrinkles in various directions, parallel to the skin surface. The lip wrinkles were improved in many cases, but the problem was that bleeding caused severe and unacceptable bruising, which sometimes resulted in hard nodules. Camirand and Doucet [3] treated scars with a tattoo gun to "needle abrade" them. Although this technique can be used on extensive areas, it is laboriously slow and the holes in the epidermis are too close and too shallow. These techniques work because the needles break old collagen strands in the most superficial layer of the dermis that tether scars or wrinkles. It is presumed that this process promotes removal of damaged collagen and induces more collagen immediately under the epidermis. The author believes that the standard technique of tattooing is too superficial to give good effects for thicker scars or for stimulating collage-

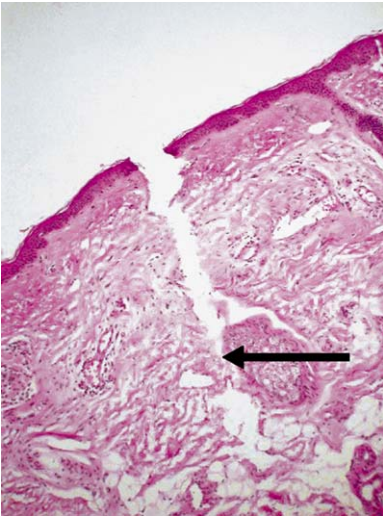


Fig. 3. Histologic section shows that the needle tract penetrates to a depth of about 1.5 to 2 mm through the papillary dermis into the reticular dermis (hematoxylin-eosin, original magnification $\times 40$).

nosis in the reticular dermis. Needles need to penetrate relatively deeply to stimulate the production of elastin fibers oriented from the deep layers of the dermis to the surface. Based on these principles, the author designed a special tool for PCI [4] (Fig. 1).

Indications for needling

Indications for percutaneous collagen induction

1. To restore skin tightness in the early stages of facial aging. This procedure is relatively minor and can safely be recommended. Some patients who are worried about cosmetic surgery may be satisfied with simple PCI. The neck, arms, abdomen, thighs, and areas between the breasts and buttocks also can be treated. Upper-lip creases can respond very well to needling (Figs. 2–4) but may give an even better result when combined with fat grafts.
2. Fine wrinkles are an excellent indication for needling of the skin.
3. Acne scarring—the skin becomes thicker and the results are superior to dermabrasion.
4. To tighten skin after liposuction.
5. Stretch marks (Fig. 5).
6. Lax skin on the arms (Fig. 6) and abdomen (Fig. 7).
7. Scars—if they are white, then they can become more skin colored.

8. Hypertrophic burn scars—PCI can safely be used in children and may avoid procedures to release contractures.

Contraindications for percutaneous collagen induction

1. Patients who have not pretreated their skin with vitamin A.
2. Presence of skin cancers, warts, solar keratoses, or any skin infection. The needles may disseminate abnormal cells by implantation.
3. Active acne or herpes labialis infections in the face or impetigo lesions anywhere on the body.
4. Patients on any anticoagulant therapy like warfarin, heparin, and other oral anticoagulants. The presence of these drugs may cause excessive, uncontrolled bleeding. Patients previously on such treatment should have their coagulation status checked before the treatment to confirm that they have a normal clotting/bleeding profile.
5. Many patients take aspirin daily for medical or health reasons. The aspirin should be stopped at least 3 days before the procedure.
6. Allergy to local anesthetic agents or general anesthesia. These patients should be assessed by a specialist anesthetist before treatment.
7. Patients on chemotherapy, high doses of corticosteroids, or radiotherapy.
8. Patients with uncontrolled diabetes mellitus.
9. Patients with an extremely rare but severe form of keloid scarring in which virtually every pinprick becomes a keloid. Patients often have keloids on the palms of the hands or soles of the feet.

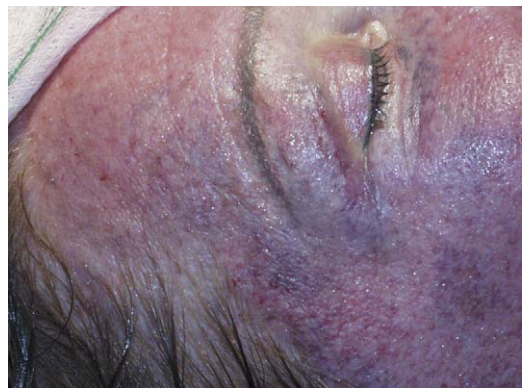

Fig. 4. Appearance of the skin immediately after PCI. The skin has been cleaned thoroughly and areas of cyanosis can be seen.

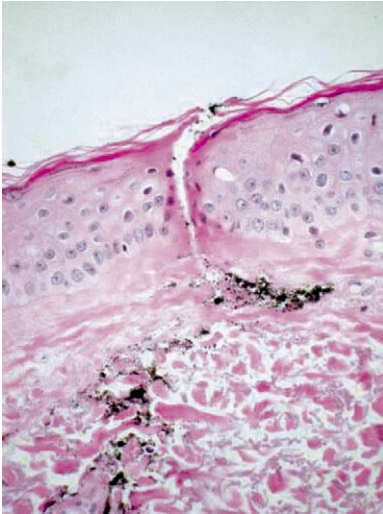


Fig. 5. This slide illustrates the ease with which Indian ink passively penetrates the skin after needling. Skin was removed from the upper eyelid and then later needled. Following needling, Indian ink was applied to the surface and allowed to dry before the specimen was placed in formalin for histologic examination. Notice that the ink has penetrated the papillary dermis. The lesson from this procedure is that clinicians and patients must be cautious about what is applied to the surface of the skin after needling.

Preparing the skin

To achieve youthful skin, one needs the skin to be functionally as young as possible. Most patients coming for rejuvenation have photoaging and this needs to be addressed before attempting any PCI. Photoaging not only is due to the actual ultraviolet damage of dermal tissues but also is the result of a chronic deficiency of vitamin A. [5] The first step toward skin health is to topically replace photosensitive vitamin A [6] and the other antioxidants vitamins C and E and carotenoids, which are normally lost on exposure to light. Vitamin A is utterly essential for the normal physiology of skin and yet it is destroyed by exposure to light so that it is prevented from exerting its important influence on skin and preserving collagen. Vitamin A is believed to control between 350 to 1000 genes that control normal function, proliferation, and differentiation of cells. One cannot exaggerate the value of vitamin A in a rejuvenation program for skin, especially with PCI, because in this case, we are specifically trying to stimulate cells to induce collagen to their maximum. Vitamin A in physiologic doses will stimulate cell growth, the release of growth factors, angiogenesis [7], and the production of healthy new collagen. The DNA effects of vitamin A interact in parallel with the growth factors released by PCI. Adequate nourishment of the skin with vitamin A (not necessarily as

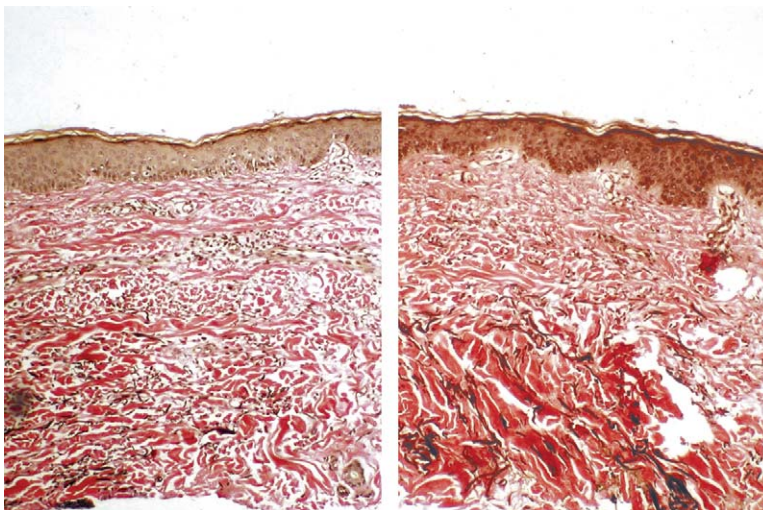


Fig. 6. (Left image) Histology shows thigh skin before PCI. (Right image) Six months after PCI, more collagen (pink) and elastin (brown) can be detected. Although difficult to estimate, there is at least 400% more collagen and elastin in the postprocedure histology section (Giemsa, original magnification $\times 40$).

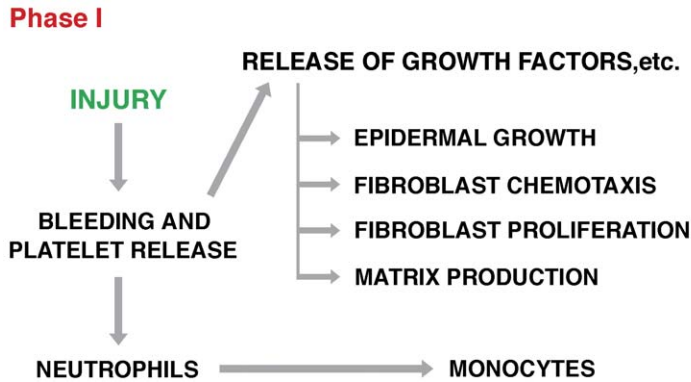


Fig. 7. Phase I of the inflammatory response showing the cascade of cytokines and growth factors following the initial injury of needling. At this stage, neutrophils are the dominant leucocytes but are gradually replaced by monocytes, the dominant leucocytes in phase II.

retinoic acid but also as retinyl esters, retinal, or retinaldehyde) will ensure that the metabolic processes for collagen production will be maximized and the skin will heal as rapidly as possible [8].

Vitamin C is similarly important for collagen formation but is destroyed by exposure to blue light. Both of these vitamins need to be replaced every day so that the natural protection and repair of DNA can be maintained. As a result, the skin will take on a more youthful appearance. The addition of palmitoyl pentapeptide or other similar peptides also will ensure that better collagen will be formed. The use of a special device for microneedling of the skin (Environ *Cosmetic* Roll-Cit, Vivida c.c., Cape Town, South Africa) will ensure that higher doses of the active ingredients get into the skin. These chemicals, however, cannot achieve really youthful skin because the collagen immediately below the epidermis has

been destroyed by years of sun exposure and the production of collagen in this area needs to be stimulated by a more targeted technique.

Technique of percutaneous collagen induction

The skin is routinely prepared by using topical vitamin A and C and antioxidants for at least 3 weeks, but preferably for 3 months if the skin is very sun damaged. If the stratum corneum is thickened and rough, a series of mild TCA peels (2.5%–5% TCA in a special gel formulation) will get the surface of the skin prepared for needling and maximize the result.

Under topical, local, or general anesthesia, the skin is closely punctured with the special tool that consists of a rolling barrel with needles at regular intervals. By rolling backward and forward with

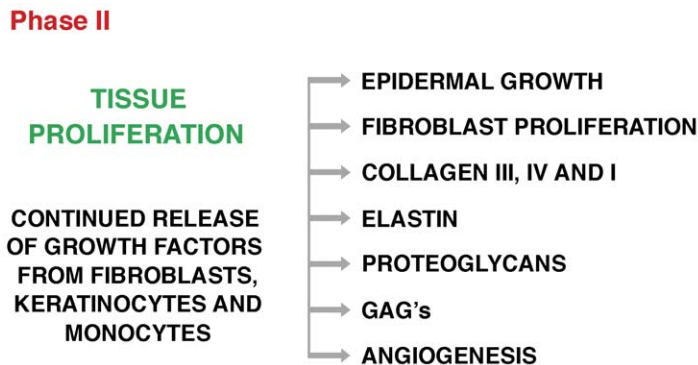


Fig. 8. Phase II of the inflammatory response, which is predominantly the stage of tissue proliferation. Monocytes, keratinocytes, and fibroblasts continue to influence and be influenced by the release of growth factors. Keratinocytes stimulate growth of the epidermis and release growth factors to promote collagen deposition by the fibroblasts. New blood vessels are created, and there is a surge of matrix deposition. GAGs, glycosaminoglycans.

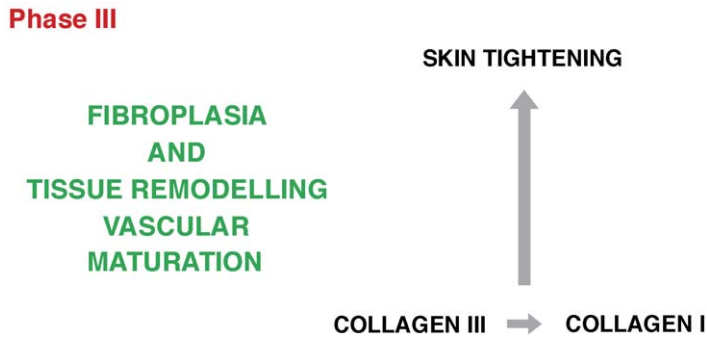


Fig. 9. The final remodeling phase of healing after PCI, which takes many months. Collagen type III is converted into collagen type I, and the skin becomes tighter. Blood supply is normalized, so the skin becomes smoother and has a natural color.

some pressure in various directions one can achieve an even distribution of the holes. The skin should be needled as densely as possible. Usually, as the needle holes get too close to each other, the needle “slips” into an established hole and so it seems impossible to over treat the skin. For very superficial small scars, I use a simple tattoo-artist’s gun as described by Camirand and Doucet [3]. When using the tattoo-artist’s machine, one has to be very careful not to overtreat an area because the skin can then be damaged because the needles plough their way through the skin and may remove the epidermis. The needles penetrate through the epidermis (Fig. 8) but do not remove it, so the epidermis is only punctured and will rapidly heal. The needle seems to divide cells from each other rather than cutting through the cells so that many cells are spared. Because the needles are set in a roller, the needle initially penetrates at an angle and then goes deeper as the roller turns. Finally the needle is extracted at

the converse angle and therefore the tracts are curved, reflecting the path of the needle as it rolls into and then out of the skin. The epidermis and particularly the stratum corneum remain intact, except for these tiny holes, which are about four cells in diameter. The needles penetrate about 1.5 to 2 mm into the dermis (Fig. 9). Naturally, the skin bleeds for a short time, but that soon stops. The skin develops multiple microbruises in the dermis that initiate the complex cascade of growth factors that eventually results in collagen production (Fig. 10). After the bleeding stops, there is a serous ooze that has to be removed from the surface of the skin. Wet gauze swabs soak up most of the serous ooze. As the skin swells, the holes are closed, the edges of the epidermis are approximated, and the ooze stops. Noxious chemicals, however, may still penetrate the skin, so only safe molecules should be used topically (Fig. 11). After this serous leak has stopped, the skin is washed thoroughly and then covered with vitamin A, C, and

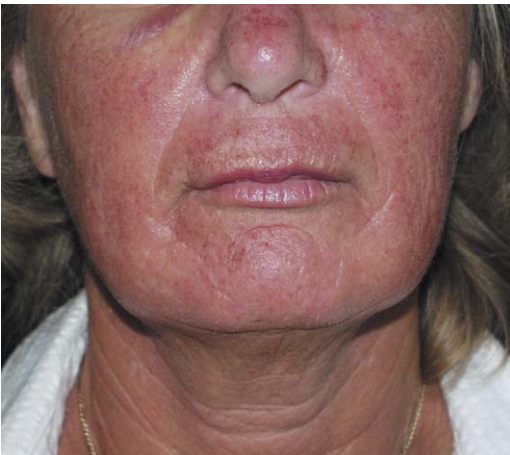

Fig. 10. Appearance of the skin 2 days after PCI.

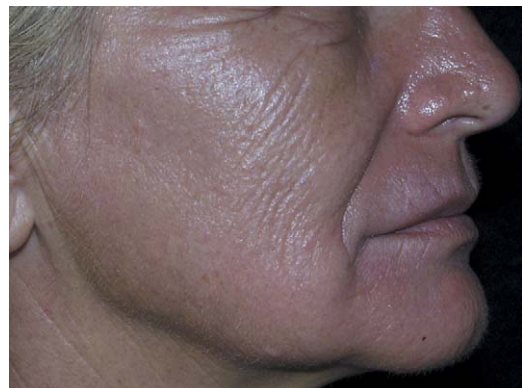

Fig. 11. Appearance of the skin 5 days after PCI. Makeup can be used from about the fourth to the fifth day without problems.

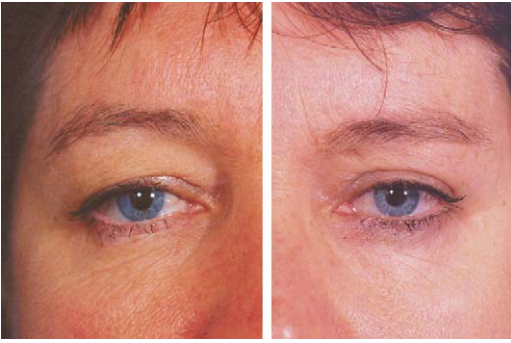

Fig. 12. Mirror image of the right eye of a patient who had PCI of the lower-eyelid skin done in conjunction with an upper blepharoplasty and lateral elevation of the eyebrow in a scarless technique devised by the author. The left image shows the right eyelid preoperatively and the right image shows the eyelid 6 months postoperatively.

E oil or cream (do not use ascorbic acid). The patient is warned that they will look terribly red and bruised, and they are encouraged to shower within a few hours of the procedure, when they return home.

Why percutaneous collagen induction works

PCI results from the natural response to wounding of the skin, even though the wound is minute and mainly subcutaneous. A single needle prick through the skin would cause an invisible response. It is necessary to understand that when the needle penetrates into the skin, this injury, minute as it might seem, causes some localized damage and bleeding by rupturing fine blood vessels. Platelets are automatically released and the normal process of inflammation commences, even though the wound is

miniscule. A completely different picture emerges when thousands or tens of thousands of fine pricks are placed close to each other and one gets a field effect, because the bleeding is virtually confluent. This promotes the normal post-traumatic release of growth factors and infiltration of fibroblasts. This reaction is automatic and produces a surge of activity that inevitably leads to the fibroblasts being “instructed” to produce more collagen and elastin. The collagen is laid down in the upper dermis just below the basal layer of the epidermis (Fig. 12).

It now becomes important to understand the process of inflammation in detail. An excellent reference on this topic is the chapter “Wound Healing” by Falabela and Falanga in *The Biology of the Skin* [9]. There are three phases in wound healing:

- Phase I: inflammation, which starts immediately after the injury
- Phase II: proliferation (tissue formation), which starts after about 5 days and lasts about 8 weeks
- Phase III: tissue remodeling, from 8 weeks to about 1 year

Phase I: initial injury

The inflammation phase starts when the needles prick the skin and rupture blood vessels and blood cells and serum gets into the surrounding tissue (Fig. 13). Platelets are important in causing clotting and releasing chemotactic factors, which cause an invasion of other platelets, leucocytes, and fibroblasts. The leucocytes, particularly neutrophils, then act on the damaged tissue to remove debris and kill bacteria. After the platelets have been activated by exposure to thrombin and collagen, they release numerous cytokines. This process involves a complex

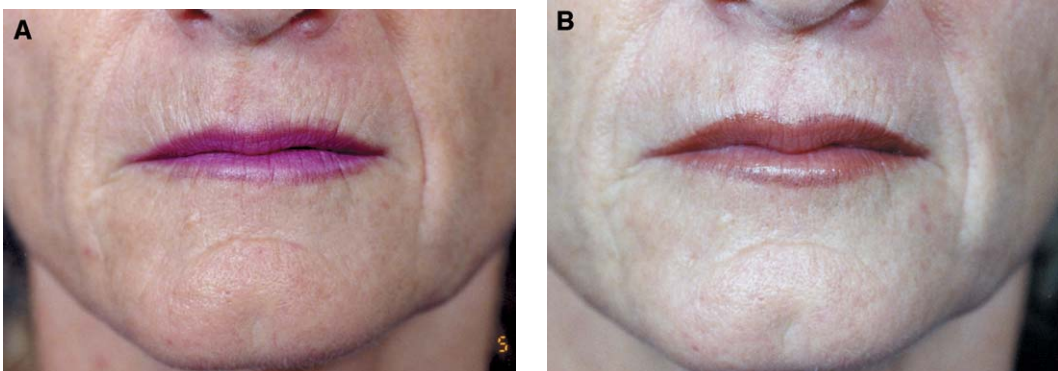


Fig. 13. (A) Upper lip before PCI showing lipstick tracking up the creases. (B) Fourteen months after one PCI treatment. No fillers have been used.

concatenation of numerous factors that are important in (1) controlling the formation of a clot (eg, fibrinogen, fibronectin, von Willebrand factor, thrombospondin, ADP, and thromboxane); (2) increasing vascular permeability, which then allows the neutrophils to pass through the vessel walls and enter the damaged area; (3) attracting neutrophils and monocytes; and (4) recruiting fibroblasts into the wounded area.

Of special interest in understanding the action of PCI are the following:

1. Fibroblast growth factor: promotes not only fibroblast proliferation but also epidermal proliferation and stimulates the production of new blood vessels. Vitamin A is an essential regulator of differentiation of fibroblasts and keratinocytes so adequate doses in the tissues are required at this stage. In anticipation of the interrupted blood supply, it should be ensured that the highest-possible normal levels of vitamin A are stored in the skin before PCI.
2. Platelet-derived growth factor: chemotactic for fibroblasts and promotes their proliferation, meaning that more collagen and elastin will be made. The need for vitamin C at this stage becomes crucial because without adequate levels of this vitamin, proline and lysine cannot be incorporated into collagen and the strands will then be defective.
3. Transforming growth factor α (TGF- α): facilitates re-epithelialization. In the case of PCI, re-epithelialization is not an important action.
4. Transforming growth factor β (TGF- β): a powerful chemotactic agent for fibroblasts that migrate into the wound about 48 hours after injury and start producing collagen types I and III, elastin, glycoaminoglycans, and proteoglycans. Collagen type III is the dominant form of collagen in the early wound-healing phase. Again, this action is heavily dependent on adequate doses of vitamin C. At the same time, TGF- β inhibits proteases that break down the intercellular matrix.
5. Connective tissue activating peptide III: also promotes the production of intercellular matrix. Fibroblasts migrate into the area, and this surge of activity inevitably leads to the production of more collagen and more elastin. Vitamin A and C again are important mediators of this action.
6. Neutrophil activating peptide-2: has a chemotactic effect for neutrophils that then migrate into the wounded area. Neutrophils are important for killing bacteria and helping to debride

tissue but, in the case of PCI, their main action is the release of cytokines that enhance the effects of the platelet cytokines (eg, platelet-derived growth factor and connective tissue growth factor).

Phase II: the period for tissue proliferation

As time passes, probably about 5 days in the case of PCI, neutrophils are replaced by monocytes (Fig. 14). The monocytes differentiate into macrophages and phagocytose the decaying neutrophils. They are very important for the later healing phases because they remove cellular debris and release several growth factors including platelet-derived growth factor, fibroblast growth factor, TGF- β , and TGF- α , which stimulate the migration and proliferation of fibroblasts and the production and modulation of extracellular matrix. With PCI, there is only extravasated blood and very little connective tissue damage to be dealt with. Bacterial infection is rare, but it has been noticed that when the needled area gets infected, greater smoothing of skin may occur, probably due to a heightened growth factor response.

In standard wounds, the inflammatory phase ends after about 5 to 6 days, as proliferation and tissue formation ensue. In these cases, the main cell is the keratinocyte. Keratinocytes change in morphology and become mobile to cover the gap in the basement membrane. The changes include retraction of tonofilaments and the dissolution of desmosomes and hemidesmosomes so that the cells can migrate. Peripheral cytoplasmic actin filaments also are developed that "pull" keratinocytes together to close the wound. These actin filaments, however, are not an important factor in PCI because re-epithelialization, or the closure of the needle holes, occurs within a few hours after needling because the gap is so small. Disruption of the basement membrane by PCI destroys the lamina lucida and brings basal keratinocytes into direct contact with the underlying collagen, which inactivates laminin and stimulates keratinocyte migration. When the keratinocytes have joined together, they start producing all the components to re-establish the basement membrane with laminin and collagen types IV and VII. A day or two after PCI, the keratinocytes start proliferating and act more in thickening the epidermis than in closing the defect.

Initially after PCI, the disruption of the blood vessels causes a moderate amount of hypoxia. The low oxygen tension stimulates the fibroblast to produce more TGF- β , platelet-derived growth factor, and endothelial growth factor. Procollagen mRNA

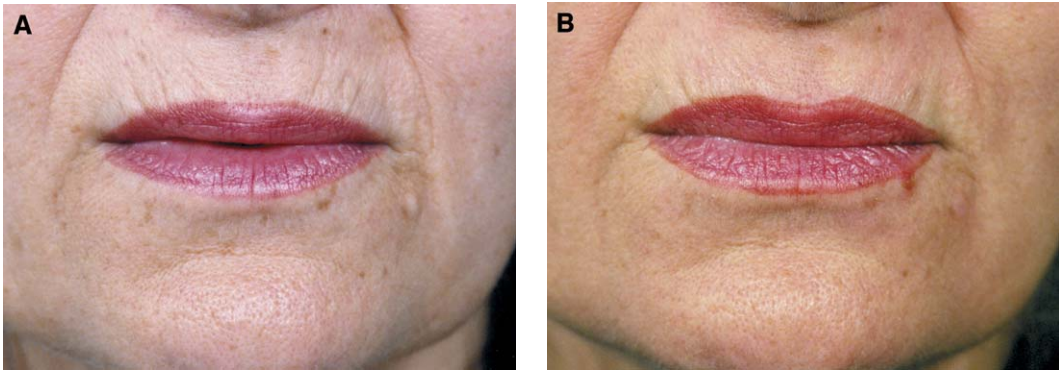


Fig. 14. (A) Before PCI. (B) One year after treatment of PCI.

also is upregulated, but this cannot cause collagen formation because oxygen is required (which only occurs when re-vascularization occurs). Collagen type III is the dominant form of collagen in the early wound-healing phase and becomes maximal 5 to 7 days after injury. The longer the initial phase, the greater the production of collagen type III.

If the injury extends deeper than the adnexal structures, then myofibroblasts may contract the wound considerably. Although the injury in skin needling extends deeper than the adnexal structures, because the epithelial wounds are simply cleft, myofibroblast wound contraction may not play a part in the healing.

A number of proteins and enzymes are important for fibroplasia and angiogenesis that develop at the same time. Anoxia, TGF- β , and fibroblast growth factor and other growth factors play an important part in angiogenesis. Fibroblasts release insulinlike growth factor that is an important stimulant for proliferation of fibroblasts themselves and endothelial cells. Insulinlike growth factor is essential in neovascularisation. Insulinlike growth factor or somatomedin-C also is one of the main active agents for growth hormone.

Integrins facilitate the interaction of the fibroblasts, endothelial cells, and keratinocytes.

Phase III – the process of tissue remodeling

Tissue remodeling continues for months after the injury and is mainly done by the fibroblasts (Fig. 15). By the fifth day after injury, the fibronectin matrix is laid down along the axis in which fibroblasts are aligned and in which collagen will be laid down. TGF- β and other growth factors play an important part in the formation of this matrix. Collagen type III

is laid down in the upper dermis just below the basal layer of the epidermis.

Collagen type III is gradually replaced by collagen type I over a period of a year or more, which gives increased tensile strength. The matrix metalloproteinases (MMPs) are essential for the conversion process. The various MMPs are generally

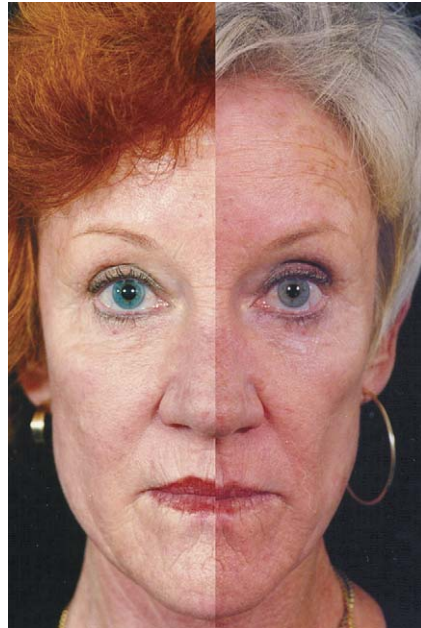

Fig. 15. Mirror image of the right side of the face preoperatively (*left image*) and 4 months after whole face needling (*right image*). The upper lip was initially needled three times 2 years before, at monthly intervals. The lower eyelid has been needled only once.

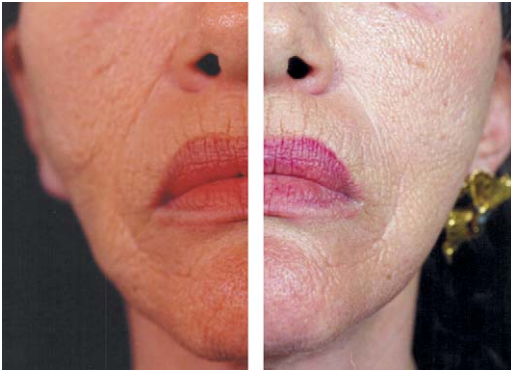

Fig. 16. Mirror image of the right side of the face of a patient previously treated with extensive silicon injections that resulted in terrible wrinkling and sagging of her facial skin. This wrinkling and sagging had improved with suction aspiration and a face-lift. (*Left image*) One year after the face-lift. The skin is still terribly wrinkled and sagging. (*Right image*) The patient 1 year after PCI of the whole face and a scarless malar lift without any skin excision.

classified as MMP-1 (collagenases), MMP-2 (gelatinases), and MMP-3 (stromelysins).

Care of the skin after percutaneous collagen induction

Immediately after the treatment, the skin looks bruised, but bleeding is minimal and there is only a small ooze of serum that soon stops. The author recommends soaking the skin with saline swabs for an hour or two and then cleaning the skin thoroughly with a Tea Tree Oil-based cleanser. The patient is encouraged to use topical vitamin A and vitamin C as a cream or an oil to promote better healing and

greater production of collagen. The addition of peptides like palmitoyl pentapeptide could possibly ensure even better results.

At home, the patient should stand under a shower for a long time, allowing the water to soak into the surface of the skin. Bathing is discouraged because of potential contamination from drains and plugs. Patients should be reminded to use only tepid water because the skin will be more sensitive to heat. While the water is running over the face or body, the patient should gently massage the treated skin until all serum, blood, or oil is removed. The importance of a thorough but gentle washing of the skin, a few hours after the procedure, cannot be stressed enough.

The skin will feel tight and may look uncomfortable in a few cases. Most patients say that the skin is a little sensitive but the major complaint is about the bruising and swelling. The following day, the skin looks less dramatic (Fig. 16) and by day 4 or 5, the skin has returned to a moderate pink flush, which can easily be concealed with makeup (Fig. 17). Men usually seem to heal faster and are less bruised than women. From day 3 or 4 onward, iontophoresis [10] and low-frequency sonophoresis of vitamin A and C could maximize the induction of healthy collagen. Iontophoresis also tends to reduce the swelling of the skin, which also helps the patient look better sooner. Low-frequency sonophoresis can be used alone without iontophoresis to enhance penetration of palmitoyl pentapeptide or other peptides (eg, palmitoyl hexapeptide, copper peptides, and so forth), which also may increase the creation of healthy collagen and elastin.

After the skin has been needled, it becomes easier to penetrate, and much higher doses of vitamin A become available in the depth of the skin. Higher doses of vitamin A may cause a retinoid reaction

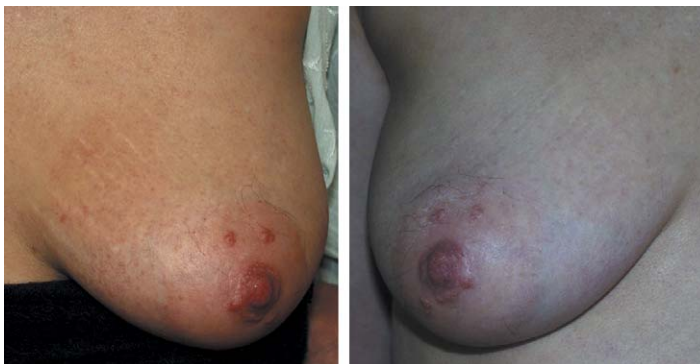

Fig. 17. Mirror image of the right breast to show stretch marks before PCI (*left image*) and 6 months after PCI (*right image*). The stretch marks have become virtually invisible.

even though the milder forms of vitamin A (eg, retinyl palmitate) are being used. This reaction will aggravate the pink flush of the skin and also cause dry, flaky skin. Needling may cause some slight roughness of the skin surface for a few days, and this condition is definitely worse when topical vitamin A is used. The clinician should ignore this and urge the patient to continue using the topical vitamin A. Patients usually anticipate that their skin will get red and do not complain much about that but become concerned about the dryness. It should be remembered that the skin has lost the important barrier function of keeping the water inside the skin. Until this barrier function is restored completely after a few days, the skin will feel dry. A hydrating cream or even petrolatum can be used to soothe the dry sensation.

When the patient has not cleaned the skin thoroughly, a fine scab may form on the surface. The formation of scabs should be discouraged because they may cause obstruction and the development of simple milia or tiny pustules. Milia are uncommon but when they occur, they should be treated by pricking and draining. Tiny pustules are more common and usually found in patients treated for acne scars. It is important to open them early and make sure that the skin has been cleaned thoroughly and that there is no serous residue on the surface. When the pustules are allowed to dry on the skin, they will form thin scabs that effectively prevent the penetration of the vitamins necessary for a successful treatment.

The patient should avoid direct sun exposure for at least 10 days if possible and use a broad-brimmed hat or scarf to protect the facial skin.

Patients may be shocked when they look in the mirror, but this procedure is a far less shocking experience than laser resurfacing.

The treatment can be repeated a month later, but the best interval between treatments is presently

unknown. If a clinician intends to achieve a smoothing comparable to a laser resurfacing, then depending on the original state, a patient may require three or even four treatments. The results that are achieved are not temporary but endure for many years. Again, it should be emphasized that this progress is utterly dependent on adequate nutrition for the skin.

Predicted appearance after percutaneous collagen induction

1. Immediately after procedure: bleeding and bruising
2. Five to 20 minutes after procedure: bleeding stops quickly; serum oozes from the skin
3. Day 1: bruised and dark purple-red appearance in light skin; puffy facial appearance; some bruising, especially close to eyes and in thin-skinned areas
4. Day 2: red-purple hue on light skin like a moderate sun burn; bruising, if any, starts to lighten; swelling may be worse on the second day in many people, and most people are not ready to be seen in public at this stage
5. Day 3: appearance still pink, with bruising getting steadily lighter; swelling reduced; some people ready to appear in public but could be conspicuous
6. Day 4 to 6: minimal swelling; bruising will take a few days to disappear; can use makeup; patient can appear in public with confidence with the use of makeup
7. Day 7: in most patients, very few signs are visible of the procedure. Most patients should be advised to stay off work for between 5 and 10 days if they deal with people at work and are sensitive about their own appearance

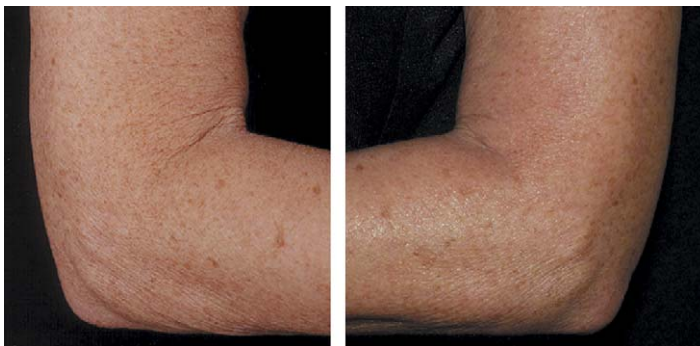

Fig. 18. Mirror image of the right arm shows wrinkling and loose skin prior to PCI (*left image*) and tighter skin 4 months after one session of PCI (*right image*).

Note about darker, pigmented skin

Most patients with dark, type IV and V skin will not show the amount of bruising that Medical Roll-Cit usually causes. The skin will appear puffy, and bruising might be visible only in thin-skinned areas such as around the eyes. Changes are a lot less visible than in light-skinned individuals. Darker-skinned patients should protect the skin from exposure to sunlight and, if necessary, a zinc oxide paste should be used to ensure ultraviolet light protection. A complication many people fear is the risk of hyperpigmentation. Tattoos are rarely hyperpigmented, even in darker-skinned people. The author has never seen hyperpigmentation in patients with darker skins (eg, African, Indian, Malaysian, Chinese, Mediterranean) that have been needed.

Results of percutaneous collagen induction

PCI has been used with success for lower-eyelid wrinkles (see Fig. 2), upper-lip lines (see Figs. 3 and 4), facial wrinkles (see Fig. 5; Fig. 18), and lax photo-damaged skin on the arms (see Fig. 7), abdomen (Fig. 19), and legs. It is also useful for reducing the appearance of stretch marks (see Fig. 6) so that they become almost invisible. It is particularly useful for acne scars and post burn scars. The scars will flatten and, after a few treatments, the mesh marks of skin grafts will be less obvious.

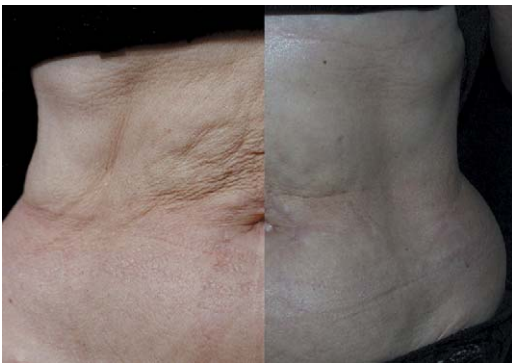

Fig. 19. Mirror image of the right side of the abdomen before PCI (*left image*) and 4 months after PCI (*right image*) showing smoothening of the abdominal skin. A second session of PCI will smoothen the redundant skin.

Advantages of percutaneous collagen induction

1. PCI does not damage the skin. Histology has shown that the skin is indistinguishable from normal skin and that the epidermis may show more dermal papillae.
2. Skin becomes thicker, with greater than a 400% increase in collagen deposition and significantly more elastin (Fig. 6).
3. Any part of the body may be treated.
4. The healing phase is short.
5. Compared with laser resurfacing, it is less expensive and the skin is healthier.
6. May be safely done in people with darker pigmented skin, without fear of hyperpigmentation.
7. The skin does not become sun sensitive.
8. Can be done on people who have had laser resurfacing or have very thin skin.
9. Telangiectasia generally improves probably because the vessels are ruptured in so many places that they cannot be repaired.
10. The technique is easy to master using a new tool that has been specially designed for the procedure and does not necessarily have to be done by a plastic surgeon or dermatologist.
11. PCI can even be done using topical anesthesia for limited areas.

Disadvantages of percutaneous collagen induction

1. Exposure to blood. This procedure is relatively bloody, much the same as dermabrasion.
2. Although PCI cannot achieve as intense a deposition of collagen as laser resurfacing, the treatment can be repeated to get even better results that will last as long if not longer than laser resurfacing.
3. Overaggressive needling may cause scarring, particularly when using a tattoo gun. This scarring does not seem to occur when using the special barrel of needles.
4. Herpes simplex is an uncommon complication and patients are instructed to use a topical virocidal if they feel the tingling feeling typical of herpes.

Summary

PCI is a simple technique and, with the right tool, can thoroughly puncture any skin easily and quickly. Although a single treatment may not give the

smoothing that is seen with laser resurfacing, the epidermis remains virtually normal. When the result is not sufficient, treatment can be repeated. The technique can be used on areas that are not suitable for peeling or laser resurfacing.

References

- [1] Orentreich DS, Orentreich N. Subcutaneous incisionless (subcision) surgery for the correction of depressed scars and wrinkles. *Dermatol Surg* 1995;21(6):543–9.
- [2] Fernandes D. Upper lip line treatment. Paper presented at the ISAPS Conference. Taipei, Taiwan, October 1996.
- [3] Camirand A, Doucet J. Needle dermabrasion. *Aesth Plast Surg* 1997;21(1):48–51.
- [4] Fernandes D. Skin needling as an alternative to laser. Paper presented at the IPRAS Conference, San Francisco, CA, June 1999.
- [5] Fisher GJ, Wang ZQ, Datta SC, et al. Pathophysiology of premature skin aging induced by ultraviolet light. *N Engl J Med* 1997;337(20):1419–28.
- [6] Fisher GJ, Datta SC, Talwar HS, et al. Molecular basis of sun-induced premature skin aging and retinoid antagonism. *Nature* 1996;379(6563):335–9.
- [7] Diaz BV, Lenoir MC, Ladoux A, et al. Regulation of vascular endothelial growth factor expression in human keratinocytes by retinoids. *J Biol Chem* 2000; 275(1):642–50.
- [8] Varani J, Fisher GJ, Kang S, et al. Molecular mechanisms of intrinsic skin aging and retinoid-induced repair and reversal. *J Investig Dermatol Symp Proc* 1998;3(1):57–60.
- [9] Falabella AF, Falanga V. Wound healing. In: Freinkel RK, Woodley DT, editors. *The biology of the skin*. New York: Parthenon Publishing Group; 2001. p. 281–97.
- [10] Schmidt JB, Binder M, Macheiner W, et al. New treatment of atrophic acne scars by iontophoresis with estriol and tretinoin. *Int J Dermatol* 1995;34(1):53–7.